

# Treatment of male varicoceles by transcatheter polidocanol foam sclerotherapy: evaluation of clinical success, complications, and patients' satisfaction with regard to alternative techniques

Alma Ali · Stefan Wirth · Karla Maria Treitl ·  
Marcus Treitl

Received: 26 December 2014 / Revised: 10 February 2015 / Accepted: 18 February 2015  
© European Society of Radiology 2015

## Abstract

**Objectives** We report our experience with polidocanol foam sclerotherapy with no additional coils, evaluating clinical success, patients' satisfaction, and complications.

**Methods** We conducted a retrospective study of 141 patients with 146 varicoceles (mean age: 29.3 years; range: 13 – 60 years) who underwent foam sclerotherapy with polidocanol 2 % (range: 2 – 12 ml) in an outpatient setting between January 2007 and December 2013. For the follow-up, telephone interviews with the patients were conducted (mean follow-up time: 46.4 months, standard deviation: 20.17 months).

**Results** The technical success rate was 91.8 %. There was a 55.8 % response rate to the telephone interviews. Follow-up revealed a clinical success rate of 83.9 % and a persistence or relapse rate of 16.1 %. Of the patients, 81.9 % were absolutely satisfied with the outcome. In 94.9 % of cases, pain or discomfort resolution was reported, and in 97 % of cases, aesthetic issues were no longer a problem. Of partners, 63.2 % achieved pregnancy, and in 50 % of patients with preprocedural testicular atrophy, catch-up growth was observed. One patient with pampiniform plexus phlebitis received inpatient treatment with no long-term damage recorded.

**Conclusions** Polidocanol foam varicocele sclerotherapy is a safe and effective procedure, with a high rate of patients' satisfaction, clinical and technical success, and considerable catch-up growth and pregnancy achievement.

## Key Points

- Varicocele treatment using polidocanol foam sclerotherapy is a safe and effective procedure.
- It is easily feasible in an outpatient setting.
- The clinical and technical success rates are high.
- It shows a high rate of patients' satisfaction and symptom resolution.
- Postinterventional catch-up growth and pregnancy achievement are considerable.

**Keywords** Varicocele · Sclerotherapy · Polidocanol · Radiology · Interventional · Phlebography

## Abbreviations

DNA	Deoxyribonucleic acid
Fr	French
NBCA	N-butyl-cyano-acrylate
NBCA-	N-butyl-cyano-acrylate+
MS	methacryloxysulfolane
STS	sodium tetradecyl sulfate

## Introduction

Varicocele, the most common correctable cause of male infertility [1], can be treated in multiple ways. First, there are the endovascular methods, which include embolization using coils [2–4], detachable balloons [5], tissue adhesives (e.g. N-butyl-cyano-acrylate, NBCA, or N-butyl-cyano-acrylate+

A. Ali (✉) · S. Wirth · K. M. Treitl · M. Treitl  
Institute for Clinical Radiology, Hospital of the Ludwig-Maximilians  
University of Munich, Nussbaumstr. 20, 80336 Munich, Germany  
e-mail: alma\_ali91@yahoo.com

methacryloxysulfolane, NBCA-MS) [6–9], hot contrast material [10], gelatin sponges [10] or Amplatzer vascular plugs [11], foam or liquid sclerotherapy using sclerosing agents (e.g. polidocanol [12–14], sodium tetradecyl sulfate [15–17], sodium morrhuate [18], or ethanolamine oleate [19]), and sclero-embolization, which uses sclerosants in combination with coils and/or balloons [20–22], (Fig. 1 and 2).

Second, varicocele can also be treated with a spectrum of surgical techniques comprising open varicocelectomy [23, 24], laparoscopic ligation [24], and microscopic varicocelectomy [25, 26].

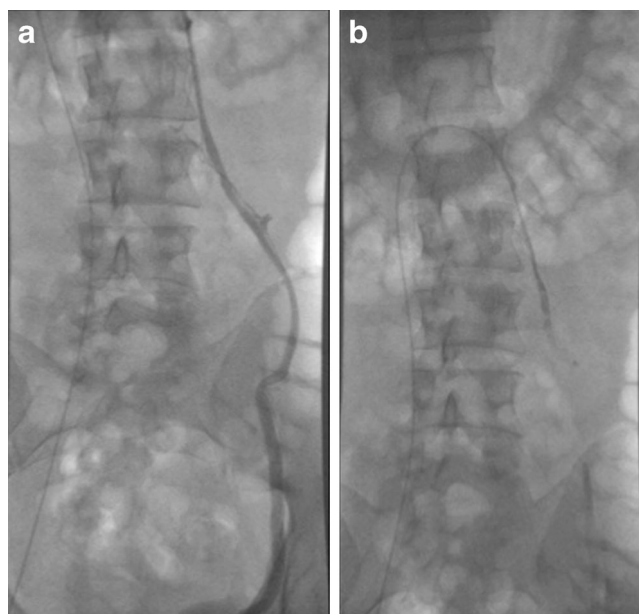
Because of the different symptoms varicocele patients may present, clinical follow-up evaluating patients' satisfaction is necessary.

The aim of this study is to analyze the outcome of sclerotherapy using isolated transcatheter polidocanol 2 % injection with regard to the following study end-points: varicocele recurrence, pain resolution, pregnancy achievement, testicular swelling resolution, catch-up growth, and assessment of procedure-related complications. Moreover, we reviewed the literature of the last 10 years on sclerotherapy and alternative techniques, also comparing our method to both endovascular and surgical approaches.

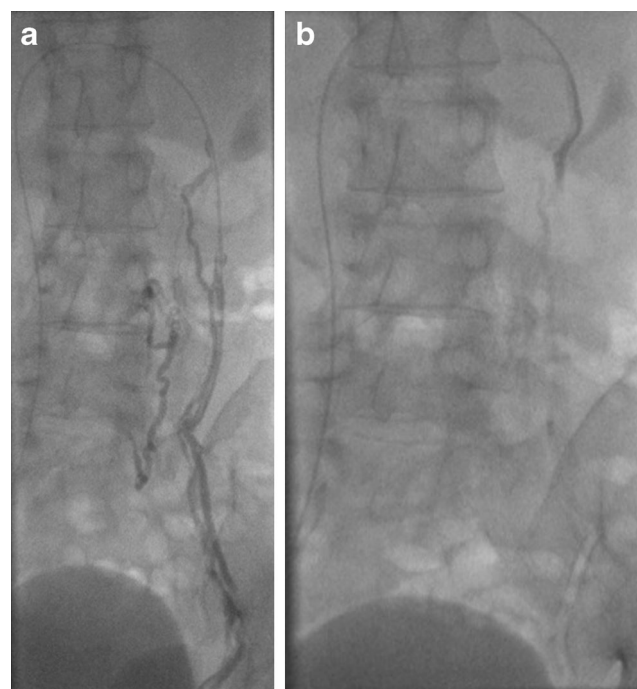
## Materials and methods

### Patients

We conducted a retrospective study of 141 patients with 146 varicoceles who underwent percutaneous sclerotherapy



**Fig. 1** **a**: Image of a Baehren type 3 varicocele before sclerotherapy. **b**: The same varicocele, as in Fig. 1a, after sclerotherapy



**Fig. 2** **a** Image of a Baehren type 2 varicocele with multiple collateral pathways to lumbar veins, before sclerotherapy. **b**: The Baehren type 2 varicocele after sclerotherapy

between January 2007 and December 2013. Patient demographics, imaging data, periprocedural parameters and complications, technical aspects, history of previous varicocele repair, and clinical grading of the varicoceles were recorded. Clinical grading was determined according to the Dubin and Amelar classification [27]; no subclinical varicoceles were considered. Patients' characteristics are listed in Table 1.

Indications for treatment included testicular pain and/or discomfort, infertility, testicular atrophy, testicular or inguinal swelling, palpable 'bag of worms', and prophylactic treatment.

**Table 1** Patient characteristics

No. of patients (total)	141
No. of varicoceles	146
Affected side	135 (92.5 %) left-sided 1 (0.68 %) right-sided 5 (3.4 %) bilateral
Age range	13–60 years (mean: 29.3 years; median: 27 years)
Grade	118 (80.8 %) Grade III 25 (17.1 %) Grade II 3 (2 %) Grade I
No. of recurrent varicoceles included in the study	8 (5.5 %)
Mean ISV diameter	5.2 mm (range: 1.9–9 mm)

## Venography and transcatheter sclerotherapy

Sclerotherapy was performed in an outpatient setting. We placed a lead testicle pouch over the testes to limit gonadal radiation exposure. With the patient in the supine position, the right femoral vein was punctured under local anaesthesia. Using the Seldinger technique, a 0.035-inch (0.89 mm) angled hydrophilic guidewire (Radifocus®; Terumo; Tokyo; Japan) and a 4 Fr Cobra C2 catheter (Radifocus® Optitorque®; Terumo; Tokyo; Japan) were introduced and advanced under fluoroscopic guidance into the left renal vein. The internal spermatic vein was then superselectively catheterized and contrast medium was injected at the level of the orifice while the patient performed the Valsalva manoeuvre to determine venous reflux and valve incompetence. If the orifice of the internal spermatic vein could not be catheterized, a renal venography was performed in order to visualize the insertion of the refluxing vein and to identify unusual anatomy. In some cases, we encountered difficulties with the stiffness of the standard Cobra catheter and we subsequently used a 4 Fr GlideCath® hydrophilic coated catheter (Terumo; Tokyo; Japan), which allowed for a smoother passage and a more flexible navigation of tortuous veins. Sheath placement was, therefore, not necessary, as the GlideCath® catheter alone was flexible enough to prevent vein lesion and allow cannulation.

In one case though, we experienced difficulty even with the GlideCath® catheter because of unusual venous anatomy (Baehren Type 2), and as a result, we successfully used a Progreat® co-axial microcatheter additionally to the GlideCath® catheter, also without using a sheath.

In the case of the right-sided and five bilateral varicoceles, the right internal spermatic vein was selectively catheterized using a 4 Fr Simmons 1 sidewinder catheter (Radifocus® Optitorque®; Terumo; Tokyo; Japan).

Varicocele anatomy was determined according to the classification by Baehren et al [28] for the left side (Table 2) and by Siegel et al [19] for the right side. Of the right-sided varicoceles, two were classified as Siegel type 1 and two as Siegel type 2 and 3, respectively.

In order to perform sclerotherapy, one syringe containing polidocanol (Aethoxysclerol) at 2 % (range: 2 – 12 ml; mean: 6.022 ml; median: 6 ml; standard deviation: 1.86 ml; interquartile range: 2 ml) was mixed through a three-way stopcock with another syringe containing unfiltered room air (1:1 ratio) to create foam sclerosant. Before administering the foam sclerosant, we injected about a 0.5-ml air bubble that could be visualized under fluoroscopy. The foam was then administered under fluoroscopic guidance through the catheter that was placed, in most of the cases, at the level of the sacroiliac joint. In the presence of further collateral vein origins below the sacroiliac joint, the catheter was positioned at the level of these origins to allow for extensive sclerotherapy of all

**Table 2** Venographic anatomy

Baehren Anatomic Type	Features	No. of patients <sup>a</sup>
0	Single ISV with sufficient valves and no evidence of venous reflux	4 (3.3 %)
1	Reflux into a single ISV without duplication	30 (25 %)
2	Reflux into a single ISV that communicates with collaterals to Vv. lumbales and/or V. cava inferior (Fig. 2a)	12 (10 %)
3	Reflux into an ISV showing two or more parallel collaterals that eventually coalesce into a single trunk (Fig. 1a)	71 (59.2 %)
4	Reflux into a single ISV that communicates with renal and perirenal collaterals	2 (1.7 %)
5	Renal vein anomaly (bifurcation of the renal vein, circumaortic renal vein)	1 (0.8 %)

<sup>a</sup>for 22 varicoceles no images were available

collaterals. During polidocanol injection, the patient performed the Valsalva manoeuvre once again to prevent reflux of the sclerosing agent into the renal vein, while the interventional radiologist compressed manually the inguinal ring for 1 min to prevent sclerosant from passing in the pampiniform plexus, which would lead to a thrombophlebitis of the pampiniform plexus. During Valsalva, the position of the air bubble that we previously injected was monitored, in order to determine how intensely the manoeuvre was to be performed by the patient. As no contrast medium was added to the foam, we could not, however, absolutely rule out reflux of the sclerosant into the renal vein.

After the desired result of vein obstruction was attained, the catheter was withdrawn and the puncture site was compressed manually for 5 – 10 min, followed by compression with a sandbag for 2 h after sterile wound dressing. Patients were ordered to stay in bed for 2 h, during which they were closely monitored. In addition, they were advised to avoid strenuous exercise and heavy lifting for 5 days and also to avoid hot showers for a day. In case of postprocedural pain, patients were given three doses of 400 mg/day of Ibuprofen.

#### Follow-up

For the follow-up, we used patients' medical records and conducted telephone interviews with the patients, requesting information concerning postinterventional visits to the referring urologist, indication for treatment, history of previous varicocele repair, partial or complete varicocele resolution, complications, pain or discomfort related to the procedure, varicocele recurrence or persistence, symptom resolution, postprocedural

varicocele repair, and patients' satisfaction. Depending on the initial indication, we asked in addition, in cases of infertility, whether pregnancy was achieved and, in cases of testicular atrophy, whether catch-up growth was observed. Catch-up growth was observed by patients themselves and documented in the telephone follow-up.

Mean and median follow-up time were 46.4 and 52 months, respectively (range: 6-85 months; standard deviation: 20.17 months; interquartile range: 30 months).

We graded patients' satisfaction on a scale from 1 to 5, 1 signifying 'absolutely satisfied' and 5 signifying 'absolutely unsatisfied'. Preprocedural pain, as well as pain related to the procedure, were assessed using the quantitative pain scale (0-10).

#### Statistical analysis

Descriptive statistical analysis was performed using IBM SPSS Statistics version 22 and Microsoft Excel for Mac 2011 version 14.

## Results

#### Technical success

Of the 146 varicocele sclerotherapy attempts, 134 sclerotherapies in 129 patients were technically feasible (91.8 % technical success rate). The 12 technical failures occurred in the following cases: three varicoceles were recurrent and the vein could not be venographically identified due to prior endovascular treatment; four varicoceles had sufficient valves, making the catheterization of the vein impossible; and two varicoceles had a difficult venous anatomy (Baehren type 2), leading to failure. In another three cases, the origin of the internal spermatic vein could not be selectively catheterized, a renal venography was made and no orifice could be found.

#### Clinical success

We contacted the 129 patients, in whom the sclerotherapy proved feasible and 72 of them responded to the interview questions (55.8 % response rate). The 72 patients are the group the clinical results are mainly based on. We defined clinical success as the complete resolution of varicocele.

We achieved a clinical success rate of 83.9 %, a complete resolution of the disease was documented by the referring urologist in 52 out of 62 patients (10 patients did not complete a urological follow-up visit after the procedure). One case of persistence, three cases of relapse, and six cases of partial resolution were noted, with a resulting persistence and relapse rate of 16.1 %.

In 37 out of 39 cases (94.9 %) a complete resolution of pain or discomfort was recorded; in one case, there was no change in pain or discomfort and in another, the pain worsened after the procedure (the median pain prior to sclerotherapy was 5 out of 10 on the quantitative pain scale).

Thirty-two out of 33 cases (97 %) of testicular swelling or palpable 'bag of worms' resolved. In one case there was no change in swelling or appearance.

Three out of six cases (50 %) of testicular atrophy showed postprocedural catch-up growth. Two cases showed no change, whereas in one case, the atrophy worsened.

Of 19 patients who desired pregnancy, 12 achieved pregnancy with a resulting pregnancy achievement rate of 63.2 %.

Concerning patients' satisfaction, of the 72 patients, 59 (81.9 %) were absolutely satisfied with the outcome; six (8.3 %) were satisfied; one (1.4 %) was neutral; three could not give an answer (4.2 %); and another three were not satisfied (4.2 %). No patient was absolutely unsatisfied. The three cases of unsatisfied patients comprised a case with varicocele persistence and 45 days lasting flank pain and two cases with varicocele relapse.

#### Complications and periprocedural pain or discomfort

We encountered the following periprocedural complications: one case of vein lesion with contrast agent extravasation, two cases of perioral and lingual paraesthesia, one case of acute nausea, one case of pruritus and erythema, and one case of hypotensive reaction with 110/80 mmHg.

The one case of vein lesion with contrast agent extravasation did not require treatment and the patient had no clinical sequelae, as it proved to be self-limiting. We interpreted the two cases of perioral and lingual paraesthesia, as well as the case of acute nausea as allergic reactions to contrast agent. Therefore, two ampoules of cimetidine and dimetindene, respectively, were administered in each case, after which symptoms resolved. The patient with pruritus and erythema was treated with two ampoules of cimetidine and dimetindene, respectively, and 1,000 mg prednisolone. The case of hypotensive reaction resolved spontaneously after 10 min, not requiring further treatment.

The postprocedural complications are based on the 72 patients, who responded to the telephone interviews. A pampiniform plexus phlebitis was diagnosed in one patient who developed severe swelling with pain after sclerotherapy and received inpatient treatment for 5 days. There were no long-term complications, such as testes loss. Other postprocedural complications include four cases of temporary inguinal/scrotal swelling, four cases of temporary minimal groin hematoma, and two cases of temporary pain in the flanks.

Twenty-four of the 72 interviewed patients (33.3 %) reported pain or discomfort during the procedure. The median pain

or discomfort during the procedure was 3.5 on the quantitative pain scale with a range of 1 to 10.

Postsclerotherapy pain or discomfort related to the procedure was reported by 30 of 72 patients (41.7 %). The median postprocedural pain or discomfort was 3 on the quantitative pain scale with a range of 1 to 8 and a median duration of 2 days (maximum: 45 days; minimum: 1 day).

## Discussion

### Percutaneous sclerotherapy versus surgery

Percutaneous varicocele sclerotherapy is a rapid and minimally invasive procedure, usually performed in an outpatient setting and not requiring general anaesthesia.

Radiologic treatment offers the advantages of less patient discomfort and rapid recovery in comparison to the more invasive approach of varicocelectomy [29]. In addition, surgery does not provide the possibility to visualize the exact varicocele anatomy.

Concerning open varicocelectomy techniques – Palomo (high retroperitoneal ligation of the spermatic vein) and Ivanissevich (ligation within the inguinal canal) – high recurrence and complication rates have been reported, with complications ranging from hydrocele formation, testicular artery injury, epididymitis, or vas deferens occlusion, which are rarely seen with sclerotherapy [30].

Laparoscopic varicocelectomy can preserve the testicular artery and in some cases also the lymphatics, lowering the risk of artery injury or hydrocele [31]. Disadvantages include the high cost, the need for an experienced surgeon, and the long operating times [30].

The microscopic inguinal or subinguinal varicocelectomy spare the testicular artery and the lymphatics, which accounts for lower recurrence rates. Hydrocele also hardly occurs. Another advantage is its possible outpatient setting as local anaesthesia is feasible [30, 31].

In 2009, Cayan et al [32] compared the outcomes of various studies on open, laparoscopic, microscopic, and radiologic embolization treatment and found that the best results (lowest overall postoperative recurrence rate and hydrocele formation rate, as well as the highest overall spontaneous pregnancy rates) occurred with microscopic varicocelectomy, while the Palomo technique showed the highest recurrence and hydrocele formation rates.

Table 3 offers a comparison regarding persistence or recurrence rates, pregnancy rates and hydrocele formation between our data and studies on the Palomo technique, laparoscopy and microsurgery, respectively.

The table shows that in comparison to these techniques, we achieved the highest pregnancy rate of 63.2 %. Our method did not lead to any hydrocele formation either, as with percutaneous sclerotherapy, the testicular artery and the lymphatics are not at risk of injury.

The lowest recurrence rates and a low hydrocele formation rate were recorded with the microsurgical methods, explained by the good identification of distended plexus pampiniformis veins and lymphatics, respectively, during surgery [30]. The complication rates in the literature are also low, between 0 and 2 %, making microsurgery the most favourable in outcome among surgical options [30].

In conclusion, sclerotherapy with polidocanol can achieve higher pregnancy rates than surgical treatment options and has the advantage of no hydrocele formation. Regarding recurrence, however, microsurgery proves to be more effective.

### Percutaneous sclerotherapy versus other endovascular treatment options

In the interventional radiology literature, technical and clinical success rates of 80 – 100 % [7, 18, 20, 21, 33] in both sclerotherapy and embolization have been reported, which are consistent with our technical and clinical success rates of 91.8 % and 83.9 %, respectively. We observed a slightly higher persistence and relapse rate (16.1 %) than those of 0 – 16 %

**Table 3** Surgical varicocele repair versus our data

Study	Number of patients	Technique	Persistence/recurrence	Pregnancy rates	Hydrocele formation
Our study	141; 72 had follow-up	Sclerotherapy with polidocanol	16.1 % (10/62)	63.2 % (12/19)	0 % (0/72)
Cayan et al (2000) [39]	232	Palomo technique	15.51 % (36/232)	33.57 % (47/140)	9.09 % (12/132)
Watanabe et al (2005) [40]	50	Palomo technique	12 % (6/50)	35.8 % (18/50)	10 % (5/50)
Watanabe et al (2005) [40]	33	Laparoscopy	6.1 % (2/33)	40.4 % (12/30)	3.3 % (1/33)
Marmar and Kim (1994) [41]	466	Microscopic subinguinal varicocelectomy	0.82 % (4/606)	35.6 % (186/466)	0.2 % (1/466)
Cayan et al (2000) [39]	236	Microscopic inguinal varicocelectomy	2.11 % (5/236)	42.85 % (57/133)	0.69 % (1/143)

described in the literature [7, 15, 20, 34], possibly due to the longer follow-up time. Kim et al. likewise describe a comparatively high persistence and relapse rate of 20 % in a study using coils alone or coils combined with 3 % STS foam [21].

Although varicocele sclerotherapy is generally safe and well tolerated with minimal complication rates [12, 15, 18], complications may appear, as with any other medical procedure. The most common complication associated with varicocele sclerotherapy is the pampiniform plexus thrombophlebitis [1], which occurs as a result of insufficient manual compression of the inguinal ring during polidocanol injection, allowing the sclerosant to pass in the pampiniform plexus. It is usually treated with oral corticosteroids, antibiotics, and pain medication [1]. We observed one such case. As polidocanol induces an inflammatory reaction resulting in endothelial necrosis and secondary phlebitis with thrombosis and fibrosis of the vein [7, 35], transitory pain in the flanks during and after injection is also commonly observed. Other complications include groin hematomas due to inadequate compression of the puncture site, vessel lesion with contrast agent extravasation, testicular swelling, and allergic reactions. Possible complications that were not seen in our study population include pulmonary embolism, venous spasms, oedema of the scrotum, and intra-arterial puncture [14, 18].

Sclerotherapy has been proven to improve not only testicular function and seminal parameters, increasing sperm density, motility and morphology, and serum inhibin B levels [12, 13, 18], but also pregnancy rates. In a study using STS foam sclerotherapy, Gandini et al. achieved improvement of sperm density, motility and morphology, as well as a pregnancy rate of 39 % [16]. In the present study, we achieved a higher pregnancy rate of 63.2 %, explicable by the longer follow-up time.

An important aspect is the achievement of the therapeutic goal, which may be different for each patient, pregnancy achievement, pain resolution, catch-up growth, or testicular swelling resolution. In the age of patient-centred care, patients' satisfaction is, of course, the central element. However, the individual study of these end-points is limited in the literature and focuses almost exclusively on the resolution of pain, without considering catch-up growth or aesthetic goals. We took all these aspects into account, achieving a catch-up growth rate of 50 % and a swelling resolution rate of 97 %. We also recorded a high patients' satisfaction rate.

Concerning painful varicoceles, I. Puche-Sanz et al. [3] reported significant differences in pain after coil embolization and Gandini et al. [22] described pain resolution in 96.5 % of cases after STS foam sclerotherapy, comparable to our pain and discomfort resolution rate of 94.9 %. We did not differentiate between pain and discomfort after seeing that patients had difficulties differentiating the two.

Among the endovascular methods, coils are the most commonly used. Coils obliterate the lumen, either mechanically, in the case of hydrogel-coated coils, or by inducing thrombosis,

in the case of fibered coils [35]. A disadvantage of coils is that they are not as effective in the presence of collateral vessels, which may lead to the recanalization of the varicocele. Sclerosing agents also occlude collaterals [30], preventing recurrence. Coils, as well as occlusive balloons, are also more expensive than sclerosants [36].

Tissue adhesives, introduced by M. Kunnen in 1980 [37], are nowadays represented by NBCA and NBCA-MS, a copolymer of NBCA with a lower temperature of polymerization [9]. The endothelium of the vessel is damaged as a result of the exothermic heat, activated by the polymerization of the glue [7]. However, both coil and glue embolization have been shown to lead to several complications: coil migration and corrosion, causing pulmonary embolism and late varicocele recurrence [18, 30], lipiodol pneumonia, and glued catheter [30]. Furthermore, coils may prevent further selective catheterization of the internal spermatic vein, in case the embolization was insufficient [38].

Hot contrast material is also used [10], its effect being explained by the damage to the vessel endothelium caused by the thermic injury. However, it has been reported to be painful [30].

In the present study, we used isolated polidocanol foam sclerotherapy, which presents various advantages: its extensive effect on collaterals, the steadier and more controlled distribution in the veins in comparison to liquid sclerotherapy, the decreased dilution by blood, the improved adherence to the vein, and the increase in contact time compared to liquid agents, leading to more effective results. Foam also allows the use of lower doses of sclerosant, minimizing the side effects [16, 18, 36]. We performed the sclerotherapy mostly at the sacroiliac joint level and in the presence of collateral origins below this level; we also applied sclerosant at the level of these origins. This is a further technical advantage over coil embolization, as coils mostly need to be placed far distally with a resulting higher risk of vein damage.

Table 4 offers an overview of the studies on sclerotherapy and the aforementioned alternative techniques with the highest number of patients included in the last 10 years, reviewing technique, technical and clinical success, relapse rates, and complications. The table highlights the good results of endovascular options, with the highest technical and clinical success rate, and therefore, the lowest relapse rate having been achieved by Jargiello et al using 3 % aethoxysclerol with fibered coils [20]. The highest relapse rates were seen in the study of Puche-Sanz et al [2] and Wunsch and Efinger [14] when using fibered coils alone and aethoxysclerol alone in various concentrations, respectively. Similarly, our relapse rate was 16.1 % and although we had a longer follow-up time, which allows for a more thorough relapse identification, the following question arises: does a combination of sclerotherapy and embolization provide better results? Kwak and Siegel describe in their 2014 review on interventional therapy for

**Table 4** Review of the literature for each endovascular method of treatment in the last 10 years

Authors	Technique	Technical+Clinical Success	Patients Follow-up Time	Inclusion Criteria	Results	Complications
I. Puche-Sanz et al. (2014)	Fibered coils	95.9 % TSR <sup>a</sup> 86.9 % CSR <sup>b</sup> 13.1 % relapse/persistence	154 (Jan. 07–Nov. 13) 39 months median follow-up	Primary, painful varicocele	Statistically significant differences in pain before embolization and at 3-6 months; technique especially effective in patients with high preoperative pain	4.5 % hydrocele; 0.6 % femoral phlebitis
T. Jargiello et al. (2014)	3 % Aethoxysclerol with fibered coils	100 % TSR 100 % CSR 0 % relapse/persistence	33 (Jan.06–Jun.13) 14 months mean follow-up	Recurrent postsurgical varicocele	Recurrent varicocele most frequently after a laparoscopic clipping with mid-portion vein duplication (39 %)	2 patients: venous spasm (subsided spontaneously)
P. Vanlangenhove et al. (2012)	NBCA or NBCA-MS	98.1 % TSR for NBCA 94.7 % TSR for NBCA-MS	112 veins in 83 adult patients	Impotence, clinical inconvenience, primary or secondary infertility, prophylactic embolization	Both glues equally efficient and safe, both cause a similar degree of discomfort	1 case of acute allergic reaction in the NBCA-MS group
C.M. Hawkins et al. (2012)	Boiling hot contrast medium and gelatin sponge pledgets	94 % TSR 95 % CSR 6.66 % relapse rate	15 mean follow-up 11 months	Adolescents	Promising technique that appears effective	1 patient: temporary paraesthesia of the left upper thigh
L. Li et al. (2010)	Sodium morrhuate (5 %) foam	100 % TSR 91.4 % CSR 8.6 % residual varicocele	58 (Sept. 02- Jan. 2007) 6-month follow-up	Left varicocele with abnormal semen parameters	Seminal parameters showed significant increases after treatment; foam sclerotherapy effective, safe	1 case of venous spasm, 1 case of edema of the left scrotum
R. Gandini et al. (2008)	STS (3 %) foam	97.1 % TSR 96.4 % CSR 3.6 % relapse rate	244 (Jan. 00- Jan. 04)	All patients referred for treatment	96.5 % resolution of pain, statistically significant improvement of semen parameters, 39 % pregnancy rate	1 allergic reaction to the contrast agent, 4 cases retroperitoneal leakage of contrast medium, 2 cases short episode of fever, 2 cases of testicular swelling
R. Wunsch; K.Efinger. (2005)	Aethoxysclerol 0.25-4 %	87 % TSR (last 100 patients 96 %) 89.5 % CSR 10.5 % relapse rate	Roughly 5,500 patients since 1981	All patients referred for treatment	Method very safe and efficient	0.5 % (21/4219) phlebotrombosis of the plexus pampiniformis

<sup>a</sup> TSR=technical success rate<sup>b</sup> CSR=clinical success rate

varicoceles the so-called sandwich technique, involving the placement of a nest of coils at the level of the inguinal canal prior to sclerotherapy [35]. This would prevent sclerosant reflux into the plexus pampiniformis and, simultaneously, occlude the small collaterals that otherwise would not be embolized with coils alone. The question could be answered via a prospective, randomized controlled study comparing sclerotherapy with sclero-embolization. However, although there are a few studies comparing surgery to endovascular techniques, one cannot help but notice the lack of studies comparing two endovascular techniques with each other.

The table also shows that complications after endovascular techniques are less serious than with surgery, as hydrocele formation was only observed by Puche-Sanz et al using fibered coils, and in the sclerotherapy studies, including ours, no hydrocele or arterial or vas deferens injury was observed.

## Conclusion

Treatment of male varicocele via transcatheter polidocanol foam injection proves to be a safe and effective procedure, easily feasible in an outpatient setting with high clinical and technical success rates. It shows a high rate of patients' satisfaction and symptom resolution, with considerable catch-up growth and pregnancy achievement.

Surgery-related complications, such as testicular necrosis or hydrocele formation, did not occur in any case with polidocanol sclerotherapy. Moreover, there is no need for general anaesthesia, making sclerotherapy a quick and comfortable outpatient treatment.

To compare sclerotherapy further with other endovascular treatments, such as coil or glue embolization or sclero-embolization, prospective, randomized controlled studies are needed.

**Acknowledgments** The scientific guarantor of this publication is Marcus Treitl, MD. The authors of this manuscript declare relationships with the following companies: Marcus Treitl: Consultant for Covidien, Biotronik, Endoscout. The authors state that this work has not received any funding. No complex statistical methods were necessary for this paper. Institutional review board approval was obtained. Written informed consent was obtained from all subjects (patients) in this study. None of the study subjects has ever been reported. Methodology: retrospective, observational, performed at one institution.

## References

- Bittles MA, Hoffer EK (2008) Gonadal vein embolization: treatment of varicocele and pelvic congestion syndrome. *Semin Intervent Radiol* 25(3):261–270
- Lehtihet M, Arver S, Kalin B, Kvist U, Pousette A (2014) Left-sided grade 3 varicocele may affect the biological function of the epididymis. *Scand J Urol* 48(3):284–289
- Puche-Sanz I, Flores-Martín JF, Vázquez-Alonso F, Pardo-Moreno PL, Cozar-Olmo JM (2014) Primary treatment of painful varicocele through percutaneous retrograde embolization with fibered coils. *Andrology* 2(5):716–720
- Nabi G, Asterlings S, Greene DR, Marsh RL (2004) Percutaneous embolization of varicoceles: outcomes and correlation of semen improvement with pregnancy. *Urology* 63(2):359–363
- Zuckerman AM, Mitchell SE, Venbrux AC et al (1994) Percutaneous varicocele occlusion: long-term follow-up. *J Vasc Interv Radiol* 5(2):315–319
- Vanlangenhove P, Everaert K, Van Maele G, Defreyne L (2014) Tolerance of glue embolization under local anesthesia in varicoceles: a comparative study of two different cyanoacrylates. *Eur J Radiol* 83(3):559–563
- Urbano J, Cabrera M, Alonso-Burgos A (2014) Sclerosis and varicocele embolization with N-butyl-cyanoacrylate: experience in 41 patients. *Acta Radiol* 55(2):179–185
- Sze DY, Kao JS, Frisoli JK (2008) Persistent and recurrent postsurgical varicoceles: venographic anatomy and treatment with NBCA embolization. *J Vasc Interv Radiol* 19(4):539–545
- Heye S, Maleux G, Wilms G (2006) Pain experience during internal spermatic vein embolization for varicocele: comparison of 2 cyanoacrylate glues. *Eur Radiol* 16(1):132–136
- Hawkins CM, Racadio JM, McKinney DN, Racadio JM, Vu DN (2012) Varicocele and retrograde embolization with boiling contrast medium and gelatin sponges in adolescent subjects. *J Vasc Interv Radiol* 23(2):206–210
- Rais-Bahrami S, Montag S, George AK, Rastinchad AR, Palmer LS, Siegel DN (2012) Angiographic findings of primary versus salvage varicoceles treated with selective gonadal vein embolization: an explanation for surgical treatment failure. *J Endourol* 26(5):556–560
- Di Bisceglie C, Bertagna A, Baldi M et al (2007) Varicocele sclerotherapy improves serum inhibin B levels and seminal parameters. *Int J Androl* 30(6):531–536
- Gazzera C, Rampado O, Savio L, Di Bisceglie C, Manieri C, Gandini G (2006) Radiological treatment of male varicocele: technical, clinical, seminal and dosimetric aspects. *Radiol Med* 111(3):449–458
- Wunsch R, Efinger K (2005) The interventional therapy of varicoceles amongst children, adolescents and young men. *Eur J Radiol* 53(1):46–56
- Fayad F, Sellier N, Chabaud M et al (2011) Percutaneous retrograde endovascular occlusion for pediatric varicocele. *J Pediatr Surg* 46(3):525–529
- Gandini R, Konda D, Reale CA et al (2008) Male varicocele: transcatheter foam sclerotherapy with STS - outcome in 244 patients. *Radiology* 246(2):612–618
- Granata C, Oddone M, Toma P, Mattioli G (2008) Retrograde percutaneous sclerotherapy of left idiopathic varicocele in children. *Pediatr Surg Int* 24(5):583–587
- Li L, Zeng XQ, Li YH (2010) Safety and effectiveness of transcatheter foam sclerotherapy for testicular varicocele with a fluoroscopic tracing technique. *J Vasc Interv Radiol* 21(6):824–828
- Siegel Y, Gat Y, Bacher GN, Gornish M (2006) A proposed anatomic typing of the right internal spermatic vein: importance for percutaneous sclerotherapy of varicocele. *Cardiovasc Intervent Radiol* 29(2):192–197
- Jargiello T, Drelich-Zbroja A, Falkowski A, Sojka M, Pyra K, Szczerbo-Trojanowska M (2014) Endovascular transcatheter embolization of recurrent postsurgical varicocele: anatomic reasons for surgical failure. *Acta Radiol*. doi:10.1177/0284185113519624
- Kim J, Shin JH, Yoon HK et al (2012) Persistent or recurrent varicocele after failed varicocelectomy: outcome in patients treated using percutaneous transcatheter embolization. *Clin Radiol* 67(4):359–365
- Reiner E, Pollak JS, Henderson KJ, Weiss RM, White RI Jr (2008) Initial experience with 3 % sodium tetradeceyl sulfate foam and fibered

- coils for management of adolescent varicocele. *J Vasc Interv Radiol* 19(2 Pt 1):207–210
23. Palomo A (1949) Radical cure of varicocele by a new technique; preliminary report. *J Urol* 61(3):604–607
  24. Sangrasi AK, Leghari AA, Memon A, Talpur KA, Memon AI, Memon JM (2010) Laparoscopic versus inguinal (Ivanissevich) varicocelectomy. *J Coll Physicians Surg Pak* 20(2):106–111
  25. Hopps CV, Lemer ML, Schlegel PN, Goldstein M (2003) Intraoperative varicocele anatomy: a microscopic study of the inguinal versus subinguinal approach. *J Urol* 170(6 Pt 1):2366–2370
  26. Kim SO, Jung H, Park K (2012) Outcomes of microsurgical subinguinal varicocelectomy for painful varicoceles. *J Androl* 33(5):872–875
  27. Dubin L, Amelar RD (1970) Varicocele size and results of varicocelectomy in selected subfertile men with varicocele. *Fertil Steril* 21(8):606–609
  28. Baehren W, Biehl C, Danz B (1992) Failed sclerotherapy trials with the *V. spermatica interna*. A retrospective analysis in 1141 patients with idiopathic varicocele. *RöFo* 157(4):355–360
  29. Bechara CF, Weakley SM, Kougas P et al (2009) Percutaneous treatment of varicocele with microcoil embolization: comparison of treatment outcome with laparoscopic varicocelectomy. *Vascular* 17(Suppl 3):S129–S136
  30. Iaccarino V, Venetucci P (2012) Interventional radiology of male varicocele: current status. *Cardiovasc Intervent Radiol* 35(6):1263–1280
  31. Choi WS, Kim SW (2013) Current issues in varicocele management: a review. *World J Mens Health* 31(1):12–20
  32. Cayan S, Shavakhabov S, Kadioglu A (2009) Treatment of palpable varicocele in infertile men: a meta-analysis to define the best technique. *J Androl* 30(1):33–40
  33. Baehren W, Lenz M, Porst H, Wierschin W (1983) Side effects, complications and contraindications for percutaneous sclerotherapy of the internal spermatic vein in the treatment of idiopathic varicocele. *RöFo* 138(2):172–179
  34. Riedl P, Kumpan W, Maier U, Stackl W, Lunglmayr G (1985) Long-term results after sclerotherapy of the spermatic vein in patients with varicocele. *Cardiovasc Intervent Radiol* 8(1):46–49
  35. Kwak N, Siegel D (2014) Imaging and interventional therapy for varicoceles. *Curr Urol Rep* 15(4):399
  36. Chan P (2011) Management options of varicoceles. *Indian J Urol* 27(1):65–73
  37. Kunnen M (1980) New techniques for embolisation of the internal spermatic vein: intravenous tissue adhesive (author's transl). *Röfo* 133(6):625–629
  38. Lord DJ, Burrows PE (2003) Pediatric Varicocele Embolization. *Tech Vasc Interv Radiol* 6(4):169–175
  39. Cayan S, Kadioglu TC, Tefekli A, Kadioglu A, Tellaloglu S (2000) Comparison of results and complications of high ligation surgery and microsurgical high inguinal varicocelectomy in the treatment of varicocele. *Urology* 55(5):750–754
  40. Watanabe M, Nagai A, Kusumi N, Tsuboi H, Nasu Y, Kumon H (2005) Minimal invasiveness and effectivity of subinguinal microscopic varicocelectomy: a comparative study with retroperitoneal high and laparoscopic approaches. *Int J Urol* 12(10):892–898
  41. Marmar JL, Kim Y (1994) Subinguinal microsurgical varicocelectomy: a technical critique and statistical analysis of semen and pregnancy data. *J Urol* 152(4):1127–1132